


# Journal Pre-proof

## Tactile Perception of the Hand in Children with an upper Neonatal Brachial Plexus Palsy

Sonja M. Buitenhuis MSc , Willem Pondaag MD PhD ,  
Ron Wolterbeek MD , Martijn J.A. Malessy PD PhD

PII: S0003-9993(22)01763-4  
DOI: <https://doi.org/10.1016/j.apmr.2022.11.010>  
Reference: YAPMR 58678



To appear in: *Archives of Physical Medicine and Rehabilitation*

Received date: 7 June 2022  
Revised date: 10 November 2022  
Accepted date: 22 November 2022

Please cite this article as: Sonja M. Buitenhuis MSc , Willem Pondaag MD PhD , Ron Wolterbeek MD , Martijn J.A. Malessy PD PhD , Tactile Perception of the Hand in Children with an upper Neonatal Brachial Plexus Palsy, *Archives of Physical Medicine and Rehabilitation* (2022), doi: <https://doi.org/10.1016/j.apmr.2022.11.010>

This is a PDF file of an article that has undergone enhancements after acceptance, such as the addition of a cover page and metadata, and formatting for readability, but it is not yet the definitive version of record. This version will undergo additional copyediting, typesetting and review before it is published in its final form, but we are providing this version to give early visibility of the article. Please note that, during the production process, errors may be discovered which could affect the content, and all legal disclaimers that apply to the journal pertain.

© 2022 Published by Elsevier Inc. on behalf of the American Congress of Rehabilitation Medicine

## **Tactile Perception of the Hand in Children with an upper Neonatal Brachial Plexus**

### **Palsy**

Sonja M. Buitenhuis MSc<sup>1,2</sup>; Willem Pondaag MD PhD<sup>1</sup>; Ron Wolterbeek MD<sup>3</sup> Martijn J.A. Malessy PD PhD<sup>1</sup>

<sup>1</sup> Department of Neurosurgery, Leiden University Medical Center, The Netherlands

<sup>2</sup> Department of Physical Therapy, Leiden University Medical Center, The Netherlands

<sup>3</sup> Department of Medical Statistics and Bioinformatics, Leiden University Medical Center, The Netherlands

Corresponding author:

LUMC, Attn: S.M. Buitenhuis – J11-R-83

P.O. box 9600

NL-2300 RC Leiden

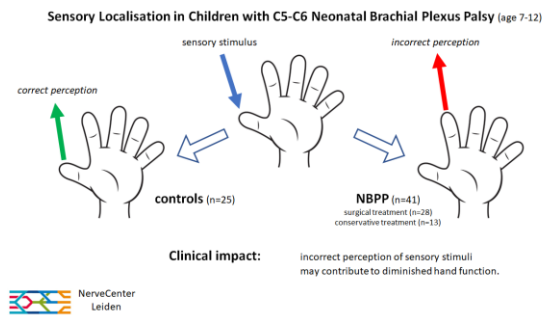
Netherlands

email: [S.M.Buitenhuis@lumc.nl](mailto:S.M.Buitenhuis@lumc.nl),

phone: +31 651 4717

Disclosures: none

## Graphical abstract



## Abstract

### Objective

To investigate factors that cause impairment of hand function in children with an upper Neonatal Brachial Plexus Palsy (NBPP), we performed an in-depth analysis of tactile hand sensibility, especially the ability to correctly localise a sensory stimulus on their fingers.

### Design

A cross-sectional investigation of children with NBPP, compared to healthy controls. The thickest Semmes-Weinstein (SW) monofilament was pressed on the radial or ulnar part of each fingertip (10 regions), while a screen prevented seeing the hand.

### Setting

Tertiary referral centre for nerve lesions in an academic hospital in The Netherlands. The control group was recruited at their school.

### **Participants**

41 children with NBPP (mean age 10.0 y) and 25 controls (mean age 9.5 y)

### **Interventions**

N.A.

### **Main outcomes Measures**

Correct localization of the applied stimuli was evaluated, per region, per finger and per dermatome with a test score. The affected side of the NBPP group was compared with the non-dominant hand of the controls.

### **Results**

The ability to localize stimuli on the tips of the fingers in children with an upper NBPP was significantly diminished in all fingers, except for the little finger, as compared to healthy controls. Mean localisation scores were 6.6 (thumb) and 6.3 (index finger) in the NBPP group and 7.6 in both fingers for controls (maximum score possible is 8.0). Localization scores were significant lower in regions attributed to dermatomes C6 ( $p < 0.001$ ) and C7 ( $p = 0.001$ ), but not to C8 ( $p = 0.115$ ).

### **Conclusion**

Children with an upper NBPP showed a diminished and incorrect ability to localize sensory stimuli to their fingers. This finding is likely one of the factors underlying the impairment of hand function and should be addressed with sensory focussed therapy.

Key Words: (MESH)

Paralysis, Obstetric

Brachial Plexus

Sensation Disorders

## **Introduction**

The neonatal brachial plexus palsy (NBPP) is a nerve traction injury that occurs during birth. The most common type involves spinal nerves C5 and C6. In more severe cases, the C7, C8 and T1 spinal nerves are damaged as well.<sup>1</sup>

An upper NBPP results in impaired or loss of force in the supraspinatus, infraspinatus, deltoid, biceps and brachioradialis muscles and thereby affects the movement of the shoulder and elbow. The involved spinal nerve C6 provides important sensory input to the hand, but the level and quality of sensation in the fingers is routinely not well documented. Treatment outcome analysis generally focusses on the amount of motor recovery of the C5, C6 deficits. In one of the rare reports where sensory recovery of the hand was studied, it appeared to be excellent.<sup>2</sup> In contrast we showed that two-point discrimination (2PD) and touch-pressure testing with Semmes-Weinstein Monofilaments (SW) of the thumb and index finger was diminished in children with an upper NBPP.<sup>3</sup> Moreover, we showed that there was a reduction

of gripforce<sup>4</sup>, and diminished dexterity<sup>3</sup>. Thus, children with an upper NBPP not only have impaired shoulder and elbow function, but impairment of hand function as well.

The identification of factors that cause the clumsiness of the hand is not complete which is why it is difficult to provide effective treatment. Finger sensation also includes the ability to localize a stimulus, next to 2PD and pressure. Therefore, we assessed in detail the ability to localize applied sensory stimuli at the fingertips in children with an upper NBPP.

### **Participants and Methods**

The study design was a cross-sectional investigation of patients with NBPP between 7 and 12 years of age who were compared to controls. Fifty children with an upper NBPP (22 boys, 28 girls, mean age 9.8 years (range 7.0 -12.8 years) and 25 healthy children (8 boys, 17 girls, mean age 9.6 years (range 7.2- 11.8 years) were recruited for this study. One child could not complete the localization test, leaving 49 children with NBPP for initial analysis. In the final analysis we only included children whose dominant hand was the unaffected side (n=41)

Patient details are presented in Table 1.

The children with NBPP were examined during regular follow-up at our tertiary referral clinic. The NBPP diagnosis was based on the obstetrical history, neurological examination and was confirmed with additional EMG studies if the patient was seen before 6 weeks of age.

The included children with NBPP showed paralysis or paresis of muscles related to the C5 and C6 spinal nerves at the age of three months. They showed absent or weak shoulder abduction, shoulder external rotation, and lack of elbow flexion against gravity with the arm brought in 90 degrees of abduction, which was tested in the supine position. The biceps muscle was palpated to assess contraction of the biceps muscle. They had active elbow

extension with active triceps muscle and active wrist extension which was at least strong enough to overcome resistance. All children had normal motor hand function, evaluated by routine clinical examination. The indication for nerve reconstructive surgery was extensively described previously.<sup>1</sup> In short, children who lacked recovery of elbow flexion executed by the biceps muscle, gleno-humeral external rotation and abduction at the age of 3 to 6 months were selected for nerve surgery. Children who were conservatively treated showed recovery of elbow flexion with active biceps muscle at 3 to 6 months of age.

In 30 children with NBPP (61%), nerve surgery was performed in early infancy, while the remaining 19 were treated conservatively. Children who were selected for nerve surgery first underwent MRI or CT myelography to assess root avulsion injury. During the operation, surgical inspection and direct nerve stimulation were performed to assess the severity of the nerve lesion. In 23 infants, the C6 function was restored by grafting from C6 to the anterior division of the superior trunk. Of the remaining seven infants, five underwent transfer of the pectoral nerve to the musculocutaneous nerve, in one patient the accessory nerve was transferred to the suprascapular nerve and in one patient neurolysis was done. In these seven children, the neural pathway from C6 to the anterior division had been left intact. Depending on the extent of the lesion, C5 was grafted to the posterior and/or anterior divisions of the superior trunk and to the suprascapular nerve. To document recovery, shoulder function was assessed using the Mallet score,<sup>5</sup> and the Medical Research Council (MRC) grade of biceps force was documented.

The control group was recruited at the Montessori school in Voorburg, The Netherlands (a regular primary school), by announcing the study on the school's message board. All children

who participated had a normal cognitive function and attended regular schools.<sup>6</sup> All children were assessed in their native language(Dutch).

In 83 % of the children with NBPP on the right side, the unaffected hand served as the dominant hand, as hand dominance may have shifted due to the lesion.<sup>7</sup> To exclude a potential confounding effect of hand dominance on sensation, we only analysed children whose dominant hand was the unaffected side. We compared the affected side of the NBPP group with the non-dominant hand of the control group (n=41). We defined the dominant hand as the hand in which a child would hold a pencil to write. A hand preference shift was assumed to have occurred if a child with a right-sided lesion had left-hand dominance, see Table 2.

#### *Sensory localization test of the fingers*

The assessment of the ability to localize applied sensory stimuli applied at the fingertips was performed by a single paediatric physiotherapist (SB) to avoid confounding in both groups. The tester has more than 41 years of experience with physical assessment and treatment of children in all age groups.

The protocol to test localization was adapted from Jerosch-Herold<sup>8</sup> and Anguelova.<sup>9</sup> The child was sitting and the elbow and supinated forearm were resting on a table. The shoulder was positioned in 0° anteflexion, 0° abduction and 0° external rotation. If this position was not possible due to lack of external rotation, the upper arm was held in a resting position in internal rotation. The dominant hand was tested first. Each fingertip was divided in two regions, radial and ulnar of the midline. The thickest SW monofilament was pressed at the radial or ulnar half for 2 seconds. The children were asked to indicate in which finger and which region they felt pressure, while a screen prevented them from seeing their own hand. During the test no feedback to the child was provided whether the correct region had been



identified. The child was shown a drawing of the hand with numbered regions of the fingertips in order to facilitate the specification of the region. (Figure 1).

Regions were tested in a quasi-random order: each region was tested two times with at least one test of another finger in between. The order of the tested regions had been determined beforehand in a quasi-random order. Each correctly identified region scored two points. When the pressure was localized in the correct half of an adjacent finger, or in the wrong half of the correct finger, one point was awarded. The scores were added up to form a sum score. For each finger a maximum score of 8 points could be reached, 4 points for each of the two regions. In this way the maximum score for each hand was 40 points (5 fingers x 2 regions x 2 test rounds x 2 points). We defined the dermatomes C6, C7 and C8 in two ways, which differed in whether area 4 (ulnar side of index finger) was attributed to C6 or to C7. We analysed the differences between the mean for each region, finger and cluster of points: C6 (1+2+3), C7 (4+5+6+7) and C8 (8+9+10), and as C6 (1+2+3+4), C7 (5+6+7), and C8 (8+9+10).

The study protocol was approved by the Medical Ethics Committee of the Leiden University Medical Centre (ABR number 48977) and informed consent was given by the parents.

#### *Statistical analysis*

Data were analysed with SPSS Statistics for Windows, version 26 (IBM Corp.Armonk, NY).

The error level was set at  $p < 0.05$ . We used the two-sample t-test to compare mean localization test scores between children with NBPP and children without NBPP for individual finger regions (radial or ulnar finger side), each finger (combined radial/ulnar

sides) and groups of regions (finger scores combined, corresponding to the dermatomes of the C6-8 levels).

## Results

In the NBPP group, 96% of the children reached Mallet score 3 or 4 regarding hand to mouth function and hand to head function. Shoulder abduction recovered to Mallet 3 or 4 in 98%. External rotation recovered to Mallet 3 or 4 in only 32% of the children. The MRC muscle force of the biceps was 4 or 5 in 98% of the children.

The NBPP group showed a larger variety in the regions where the tactile stimulus were perceived as compared to controls. The responses are presented in Table 3a and b.

The sum of the test score per region is presented in Table 4. The test scores for regions 1 through 7 differed significantly between patients and controls, but not for regions 8 through 10.

When comparing localisation per finger, which consisted of the sum of its two contributing regions, we found a significant difference for the thumb, index finger, middle finger, ring finger, but not for the little finger, see Table 5.

The comparison of the localisation test score per dermatome revealed a significant difference for the C6 and C7 dermatome, but not for C8. Because regions are attributed differently to dermatomes, we performed two different analyses: 1) C6: regions 1/2/3 and C7: 4/5/6/7 and 2) C6: 1/2/3/4 and C7:5/6/7. C8 consisted of regions 8+9+10.<sup>10,11</sup> The results of these two analyses did not differ. (Table 6) There was a statistical difference when comparing the sum score for the whole hand ( $p=0.001$ ).

Analysis of the localisation test score between the conservatively treated group (n=13) and the surgically treated group (n=28) showed a significant difference for region 2 (p=0.013). The mean score for region 2 was 3.5 (SD 0.75) for the surgically treated group and 2.77 (SD 1.01) for the conservatively treated group. The entire thumb consisting of regions 1 and 2 also scored better in the surgically treated group (p=0.030). We found no significant differences for other regions or fingers. There were no differences regarding the dermatomes C6 (p=0.40) and C7 (p=0.55).

## Discussion

Sensory input from the fingers is of eminent importance for proper cerebral control of hand function. Finger sensation contains different qualities, such as pressure threshold, two-point discrimination and localization. All sensory qualities together are processed in the cerebral cortex to enable delicate finger movements.<sup>12</sup> Previously, we showed that 2PD and the SW monofilament pressure testing in the thumb and index finger was significantly lower in children with NBPP compared to controls.<sup>3</sup> In upper NBPP lesions with clinical involvement of C5 and C6 roots, in-depth analysis of the localizing quality of the fingers has not been done so far. The present study shows that the ability to localize stimuli on the tips of the fingers in children with an upper NBPP is significantly diminished in all except for the little finger as compared to healthy controls. We found statistically significant differences per region of the fingers. Furthermore, the tactile localization was significantly diminished in dermatome C6 and C7, but not in C8.

Our findings should create awareness amongst therapists regarding the reduced sensory qualities of the hand in children with an upper NBPP. Moreover, it should encourage

therapists to address hand sensation in rehabilitation programs on a regular basis. Especially traditional sensory re-education and activity-based sensory re-education have been supported as rehabilitative interventions aiming to improve cortical plasticity and improve functioning after nerve repair.<sup>13,12</sup> Frequent application of different types of sensory stimuli to the fingers from early infancy onwards potentially stimulates central synaptogenesis and dendritic sprouting in a learning process which should ultimately lead to improvement of interpretation and appreciation of sensory input, and thereby hand function.

No differences were found between the children with NBPP who were treated conservatively or surgically, except for the thumb and region 2 of the thumb, which scored slightly better in the surgically treated group. This signifies that following nerve reconstruction, nerve regeneration provides levels of localizing ability which is at least comparable to those children with NBPP whose nerve injury was milder and therefore were not operated. In other words, the performed nerve surgery improves the level of sensibility befitting a very severe nerve injury (i.e. neurotmesis) to that of a less severe injury (i.e. axonotmesis).

This study provides detailed information of the diminished and incorrect feedback of localization stimuli. Profusely disturbed sensation of the fingers was also found after surgical repair of the median nerve in adults.<sup>14</sup> Absence of or incorrect sensory feedback results in the so called “blind” hand. Specific tasks with a blind hand can only be performed under visual control, but not without. Having a blind hand affects patient’s daily activities, for example holding a pen, searching for a key in a pocket, closing a top button or typing. Specific sensory re-education programmes have been applied in adults to facilitate understanding of the new sensory patterns provided by the hand and the rehabilitation focus is on modulation of central nervous processes rather than peripheral factors.<sup>14</sup>

Our findings showed that the localizing quality of sensory stimuli in four fingers was diminished. This can be explained by misrouting of axons during regrowth.<sup>15</sup> This factor that contributed to the mismatch in afferent feedback.<sup>9</sup> Because the NBPP lesion occurs when the brain is still developing, the impact have on motor program development is profound. It was previously hypothesized that a diminished tactile input to the brain could explain diminished embedding of movement of the affected arm, which was coined 'developmental apraxia'.<sup>16</sup> The reduced hand grip-force and dexterity may also be caused by disturbances in cerebral control development.<sup>3,4</sup> It was found in a MRI study that there was more asymmetry in both supplementary motor area and primary somatosensory areas in children with NBPP.<sup>17</sup>

A normal sensory input to the somatosensory cortex in early life is essential for the development of motor skills.<sup>16, 18, 19</sup> The nerves in the arm contain 90% sensory axons, and only 10% are motor.<sup>20</sup> This may imply that upper limb motor execution, and particularly dexterous coordination of hand movement, requires a large convergence of afferent input for feedback control. The threshold for afferent input to the sensory cortex depends on stored memory and experience, which may be altered in children with NBPP.<sup>3</sup> Another factor which may contribute to diminished hand function in upper NBPP is reduction of proprioceptive sensation. This has been shown to be reduced in the elbow joint,<sup>21</sup> but has not yet been studied in the finger joints. Interestingly, both in the control group and the NBPP group, children often asked whether they were allowed to move their fingers during testing. The children explained that they could then localise the stimulus.<sup>6</sup> This phenomenon might point to an additive effect of proprioceptive input, normal or abnormal, to correctly localize a stimulus.

An unexpected finding was that sensibility was diminished in the C7 dermatome in children who were clinically diagnosed with a nerve lesion confined to C5 and C6. Cervical dermatomes C6 and C7 are defined differently. Therefore, two different analyses were

performed in which the ulnar area of the index finger was attributed either to C6 or to C7.<sup>10, 11</sup> The result of these additional analyses did not differ. Our findings imply that in children in which the motor function deficit is clinically confined to C5 and C6 only, the C7 root may be affected sub-clinically as well. In a previous motor evaluation of axonal misrouting in adult patients with clinically an upper NBPP, it was found that misrouting was present in the triceps muscle in more than 50 %.<sup>22</sup> Alternatively, sensory overlap between the C6 and C7 dermatomes may explain this finding. A systematic review of contralateral C7 transfer revealed that sensory abnormalities after dividing the C7 root were found in the thumb, the index finger and the middle finger.<sup>7</sup>

The same localisation test as we have used here, has been done previously in adults with an upper NBPP who were treated conservatively and compared to controls.<sup>9</sup> The scores in adults did not differ significantly which does not fit with our present findings in the young. The discrepancy might be caused by differences in lesion severity, or it might indicate that sensation qualities in NBPP may still improve over a long period of time.

Future studies should include in depth hand function assessment and patient-reported outcome scores which should also include sensibility. The strength of our study is that a relatively large group of upper children with NBPP were analysed in depth covering all fingers of both hands and compared to a control group.

Our finding that the tactile perception of the fingers in children with NBPP is disturbed emphasizes the need for dedicated and focussed therapy. This might imply using visual feedback of the affected hand and stimulating both hands together in exercises.

### **Study limitation**

A drawback of the localisation test is that it required a lot of concentration from the children. As the control group were of the same age, it is unlikely that this factor affected the outcome in the NBPP group to such an extent that it explains the differences we found. Another drawback is that we did not correlate the results of the localisation test with daily activities.

A weakness of our study is that the participating children were selected from our tertiary referral clinic at the age of 7-12 years. As a consequence, surgically treated children were over-represented in the presented series. Children with a very good recovery may have been discharged from further follow-up at younger ages. Thus, we could not systematically document decreased sensibility and clumsiness of the hand in all our patients.

### **Conclusion**

Children with an upper NBPP are not only affected by the impaired motor function of the shoulder and elbow, but also by a diminished and incorrect ability to localize stimuli to the fingers. This finding may be one of the contributing factors that lead to clumsiness of the hand. Addressing tactile perception with occupational treatment may reduce these deleterious effects on hand function of these children.

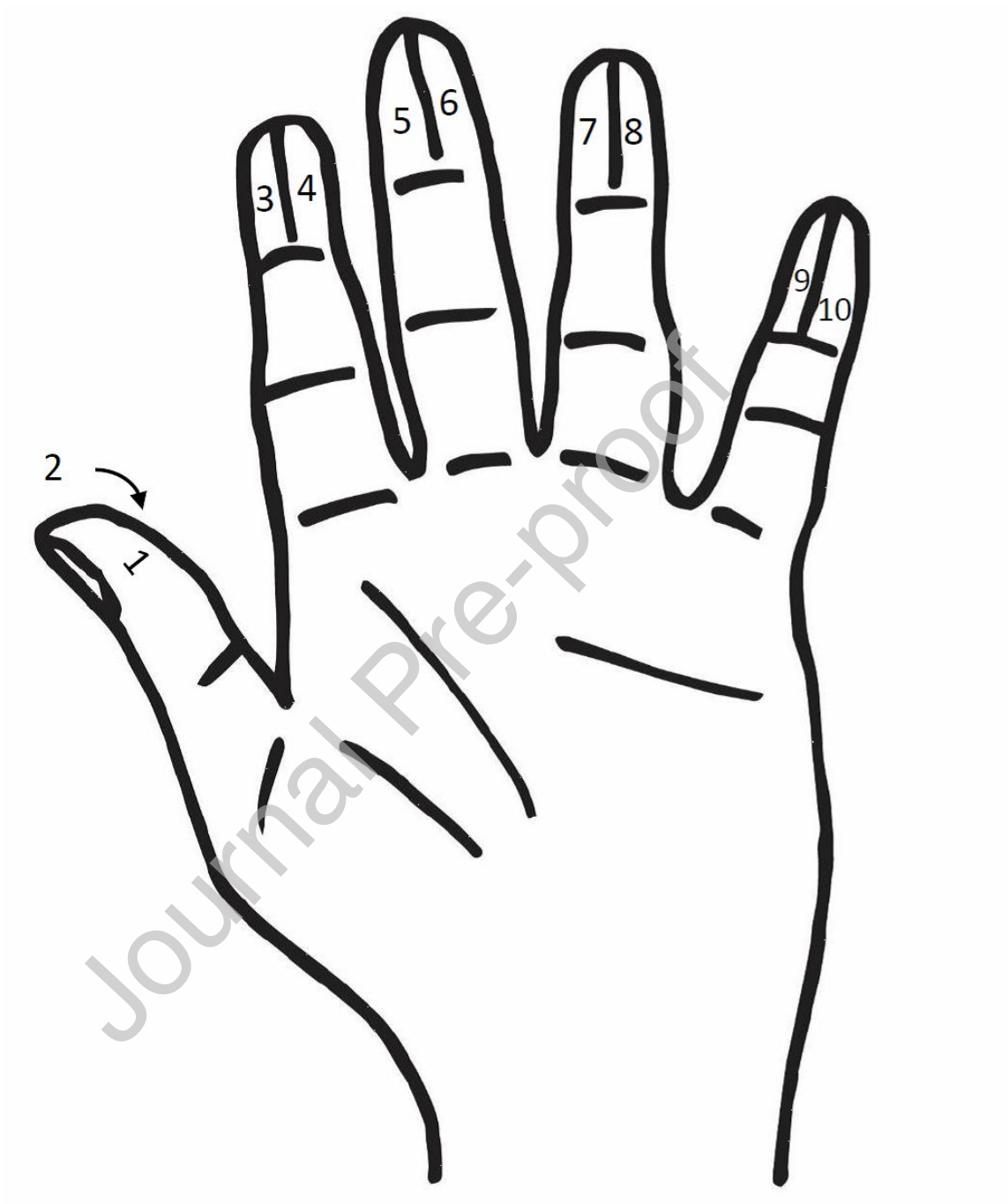
## References

1. Malessy MJ, Pondaag W. Obstetric brachial plexus injuries. *Neurosurg Clin N Am*. 2009;20(1):1-14, v.
2. Anand P, Birch R. Restoration of sensory function and lack of long-term chronic pain syndromes after brachial plexus injury in human neonates. *Brain*. 2002;125(Pt 1):113-22.
3. Buitenhuis SM, Pondaag W, Wolterbeek R, Malessy MJA. Sensibility of the Hand in Children With Conservatively or Surgically Treated Upper Neonatal Brachial Plexus Lesion. *Pediatr Neurol*. 2018;86:57-62.
4. Buitenhuis SM, Pondaag W, Wolterbeek R, Malessy MJA. Gripforce reduction in children with an upper neonatal brachial plexus palsy. *J Rehabil Med*. 2021;53(8):jrm00219.
5. Mallet J. Obstetrical paralysis of the brachial plexus. II. Therapeutics. Treatment of sequelae. Priority for the treatment of the shoulder. Method for the expression of results. [in French]. *Rev Chir Orthop Reparatrice Appar Mot*. 1972;58 Suppl 1:166-8.
6. Buitenhuis SM, Pondaag W, Wolterbeek R, Malessy MJA. Hand Sensibility in Healthy Young Children. *Pediatr Neurol*. 2018;86:52-6.
7. Yang G, Chang KW, Chung KC. A Systematic Review of Outcomes of Contralateral C7 Transfer for the Treatment of Traumatic Brachial Plexus Injury: Part 2. Donor-Site Morbidity. *Plast Reconstr Surg*. 2015;136(4):480e-9e.
8. Jerosch-Herold C, Rosen B, Shepstone L. The reliability and validity of the locognosia test after injuries to peripheral nerves in the hand. *J Bone Joint Surg Br*. 2006;88(8):1048-52.
9. Anguelova GV, Malessy MJ, Van Dijk JG. A cross-sectional study of hand sensation in adults with conservatively treated obstetric brachial plexus lesion. *DevMed Child Neurol*. 2013;55(3):257-63.
10. Greenberg SA. The history of dermatome mapping. *Arch Neurol*. 2003;60(1):126-31.
11. Keegan JJ, Garrett FD. The segmental distribution of the cutaneous nerves in the limbs of man. *Anat Rec*. 1948;102(4):409-37.
12. Lundborg G, Richard P. Bunge memorial lecture. Nerve injury and repair--a challenge to the plastic brain. *J Peripher Nerv Syst*. 2003;8(4):209-26.
13. Zink PJ, Philip BA. Cortical Plasticity in Rehabilitation for Upper Extremity Peripheral Nerve Injury: A Scoping Review. *Am J Occup Ther*. 2020;74(1):7401205030p1-p15.
14. Lundborg G, Rosen B. Hand function after nerve repair. *Acta Physiol (Oxf)*. 2007;189(2):207-17.
15. Malessy MJ, Pondaag W, Van Dijk JG. Electromyography, nerve action potential, and compound motor action potentials in obstetric brachial plexus lesions: validation in the absence of a "gold standard". *Neurosurgery*. 2009;65(4 Suppl):A153-A9.
16. Brown T, Cupido C, Scarfone H, Pape K, Galea V, McComas A. Developmental apraxia arising from neonatal brachial plexus palsy. *Neurology*. 2000;55(1):24-30.
17. Longo E, Nishiyori R, Cruz T, Alter K, Damiano DL. Obstetric Brachial Plexus Palsy: Can a Unilateral Birth Onset Peripheral Injury Significantly Affect Brain Development? *Dev Neurorehabil*. 2020;23(6):375-82.
18. Strombeck C, Krumlinde-Sundholm L, Forssberg H. Functional outcome at 5 years in children with obstetrical brachial plexus palsy with and without microsurgical reconstruction. *Dev Med Child Neurol*. 2000;42(3):148-57.
19. Sundholm LK, Eliasson AC, Forssberg H. Obstetric brachial plexus injuries: assessment protocol and functional outcome at age 5 years. *DevMed Child Neurol*. 1998;40(1):4-11.



20. Gesslbauer B, Hruby LA, Roche AD, Farina D, Blumer R, Aszmann OC. Axonal components of nerves innervating the human arm. *Ann Neurol*. 2017;82(3):396-408.
21. Brown SH, Noble BC, Yang LJ, Nelson VS. Deficits in elbow position sense in neonatal brachial plexus palsy. *Pediatr Neurol*. 2013;49(5):324-8.
22. Anguelova GV, Malessy MJ, van Zwet EW, van Dijk JG. Extensive motor axonal misrouting after conservative treatment of obstetric brachial plexus lesions. *Dev Med Child Neurol*. 2014;56(10):984-9.

Journal Pre-proof

**Figure 1** Drawing of the numbered regions on the hand**Table 1:** Patient characteristics

Demographic variables	NBPP	Control
-----------------------	------	---------

	enrolled	final analysis	
Total number	49	41	25
Nerve surgery	30	28	Not applicable
Conservatively treated	19	13	Not applicable
Mean age (years)	9.8 (SD 1.89)	10.0 (SD 1.90)	9.5 (SD 1.46)
Range (years)	7.0 -12.8	7.0 -12.8	7.2- 11.8
Boys / girls	22 / 28	19 / 22	8 / 17
Affected side left / right	26 / 24	25 / 16	Not applicable

**Table 1 Legend**

NBPP: Neonatal Brachial Plexus Palsy

**Table 2:** Hand dominance versus affected side

			<b>Dominant hand</b>	
			left	right
<b>Controls</b>			1	24
Conservative	Affected side	left	-	10
		right	3#	6*
Nerve surgery	Affected side	left	-	15
		right	13#	2*

**Table 2 Legend**

NBPP: Neonatal Brachial Plexus Palsy

The number defines the number of children within each group. # included in the analysis where children in whom the affected side was the non-dominant hand: a hand preference shift was assumed to have occurred in these children; \* not included in the analysis

**Table 3a** Comparison of region touched vs region participant felt in the non-dominant hand of the control group

Fingers	touched									
	thumb	index		middle		ring		little		
Region	1	2	3	4	5	6	7	8	9	10

felt	1	88%	8%										
	2	10%	92%										
	3	2%		90%	8%	6%							
	4			4%	90%		10%			2%			
	5			4%		76%	2%	8%					
	6			2%	2%	6%	84%	4%	16%				
	7					10%	2%	84%	0%	4%			
	8					2%	2%	4%	82%	2%			
	9										92%	2%	
	10										2%	98%	

Percentage of responses in which region the child felt the touch region. Cells were shaded darker depending on their value (<10% white, 40%-60% darkest, >90% white)

**Table 3b Comparison of region touched vs region participant felt in the affected non-dominant hand in the NBPP group**

		touched									
Fingers		thumb	index		middle		ring		little		
Region		1	2	3	4	5	6	7	8	9	10
felt	1	70%	33%		1%						
	2	27%	66%	1%	4%						
	3	2%	1%	71%	4%	5%		1%			
	4			6%	67%	1%	5%	0%	5%		
	5			13%	6%	56%	7%	15%	1%		

6		5%	11%	12%	68%	7%	10%		
7		4%	5%	17%	4%	62%	9%	1%	
8			2%	9%	15%	15%	74%	0%	
9	1%							85%	9%
10					1%		1%	13%	91%

NBPP: Neonatal Brachial Plexus Palsy

Percentage of responses in which region the child felt the touch region. Cells were shaded darker depending on their value (<10% white, 40%-60% darkest, >90% white)

Journal Pre-proof

**Table 4** Localisation test score per region

Tested regions	n	Thumb		Index		Middle		Ring finger		Little finger	
		1	2	3	4	5	6	7	8	9	10
<b>Controls</b>	25	3.8(0.60)	3.8(0.50)	3.8(0.66)	3.8(0.50)	3.4(0.77)	3.7(0.63)	3.6(0.76)	3.6(0.70)	3.8(0.66)	4.0(0.20)
<b>NBPP</b>	41	3.3(0.82)	3.3(0.90)	3.2(1.13)	3.1(1.08)	2.9(1.21)	3.2(0.97)	3.1(1.00)	3.4(0.86)	3.7(0.46)	3.8(0.44)
<b>P (t-test)</b>		0.020*	0.003*	0.017*	<0.001*	0.027*	0.030*	0.045*	0.183	0.705	0.106

NBPP: Neonatal Brachial Plexus Palsy

Results presented as mean of the sum test score per region, the maximum score per region is 4; (Standard deviation); \* significant at 5% for the two –sample t-test

**Table 5 Localisation test score per finger**

	n	Fingers				
		Thumb	Index	Middle	Ring	Little
<b>Tested regions</b>		1+2	3+4	5+6	7+8	9+10
<b>Controls</b>	25	7.6(0.87)	7.6(0.77)	7.2(1.18)	7.2(1.27)	7.7(0.68)
<b>NBPP</b>	41	6.6(1.39)	6.3(1.69)	6.2(1.77)	6.5(1.63)	7.5(0.67)
<b>P (t-test)</b>		0.001*	<0.001*	0.008*	0.040*	0.289

NBPP: Neonatal Brachial Plexus Palsy

Results presented as mean of the sum test score per finger, the maximum score is 8 per finger; (Standard deviation);\* Significant at 5% for the two-sample t-test

**Table 6 Localisation test score per dermatome**

	n	Nerves					
		C6	C7	C6-alt*	C7-alt*	C8	hand
<b>Tested regions</b>		1+2+3	4+5+6+7	1+2+3+4	5+6+7	8+9+10	Σ 1 to 10
<b>Controls</b>	25	11.3 (1.11)	14.6 (1.94)	15.1 (1.24)	10.8 (1.64)	11.4 (1.25)	37.2 (3.61)
<b>NBPP</b>	41	9.8 (1.87)	12.4 (3.13)	12.9 (2.42)	9.3 (2.38)	10.9 (1.04)	33.1 (4.97)
<b>P (t-test)</b>		<0.001**	0.001**	<0.001**	0.004**	0.115	0.001**

NBPP: Neonatal Brachial Plexus Palsy

Results presented as mean of the sum score (Standard deviation).\* alt: alternative dermatome definition (as described in the text). \*\* Significant at 5% for the two sample t-test